

PATIENT

River Erickson

SPECIES

Feline

BREED

Perisan

SEX

Male Neutered

AGE

1 year

WEIGHT

8.4lbs; 3.8kg

INTERPRETED BY

Maggie Machen Lamy,
DVM, DACVIM
(Cardiology)

IMAGING PERFORMED BY

Loetitia St-Jacques,
LVT/RVT

HOSPITAL NAME

Sierra Animal
Wellness Center

REFERRING VET

Dr. Roberts

INVOICE

24039

DATE

5/4/22

PRESENTING CLINICAL SIGNS

History: Grade 3/6 murmur. Asymptomatic.

ECHOCARDIOGRAM FINDINGS

2D, m-mode, color flow and doppler imaging is available. The left ventricular wall is normal with an asymmetric appearance. No significant hypertrophy. There is a mildly hyperechoic endocardium. The right ventricle is normal. There is no left atrial enlargement present. No right atrial enlargement present. Normal RVOT velocity. Abnormal anterior motion of the mitral valve is seen, causing a mildly elevated LVOT velocity on color flow (not captured on Spectral Doppler). The anterior leaflet of the MV is mildly thickened, consistent with dysplasia. There is trace eccentric secondary mitral regurgitation present. No TR. No other obvious valvular regurgitation is present. There is no pericardial effusion noted. No pleural effusion appreciated.

CARDIAC CHART

FELINE CARDIAC PARAMETERS	BODY WEIGHT (kg)	HR (BPM)	IVSd (cm) (Moise, Pipers)	LVIDd (cm) (Moise, Pipers)	LVWd (cm) (Moise, Pipers)	FS (%)	EF (%)
NORMAL PARAMETER	-----	150-240	0.35-0.55	<2 (mean 1.5)	3.5-0.55	35-67	80-100
PATIENT	3.8	NM	0.4	1.2	0.49	52	90
FELINE CARDIAC PARAMETERS	LA/AO (Boon)	LA/AO HEART BASE (Swe) (Abbott)	LA 2D short axis Base view (cm) (Abbott)		LVOT VEL (m/s)	RVOT VEL (m/s)	E max (m/s)
NORMAL	<1.5	<1.3	<1.2		<1.6	<1.3	<0.9
PATIENT	NM	1.3	1.0		1.8	0.9	NM

**Note: All measurements based upon multi-modal images and methods. An average value is reported.
Adapted from June Boon, Veterinary Echocardiography, 1998
Abbott J & MacLean H JVIM 2006;20: 111-119, Moise et al. Am J Vet Res 47:1476, 1986. Pipers et al. Am J Vet Res 40:882, 1979.*

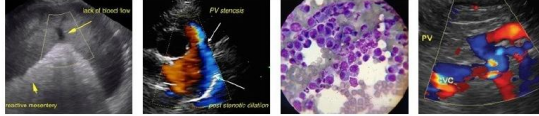
INTERPRETATION OF THE FINDINGS & FURTHER RECOMMENDATIONS

The cause of the murmur is mitral valve dysplasia leading to a mild obstructive LVOT flow pattern and secondary mitral regurgitation. There is no left atrial dilation or LV hypertrophy, indicating the risk of spontaneous CHF and/or a thrombotic event is currently low.

While no medications have been shown to definitively alter long term outcome at this stage of disease, atenolol is often initiated to decrease the outflow obstruction. In cases of solely primary MV dysplasia this can lead to improvement in the degree of obstruction and hypertrophy. Given the mild nature of disease without LVH or LAE it is reasonable to revisit in the future and assess for progression prior to utilizing medications.

Monitor at home for any respiratory signs or evidence of blood clot events (neurologic change, paralysis, etc.).

Long term prognosis is guarded given the age of the patient and highly variable nature of asymptomatic feline heart disease. Many cats will remain asymptomatic until mid-life or beyond.



PATIENT

River Erickson

Close monitoring for progression of LA dilation in the future will help determine long term prognosis.

SPECIES

Feline

PLAN

Screening blood pressure and T4 are recommended, then monitor yearly in a young cat.

BREED

Perisan

Recommend recheck echocardiogram in 6-12 months to assess for progression, sooner if clinical issues arise.

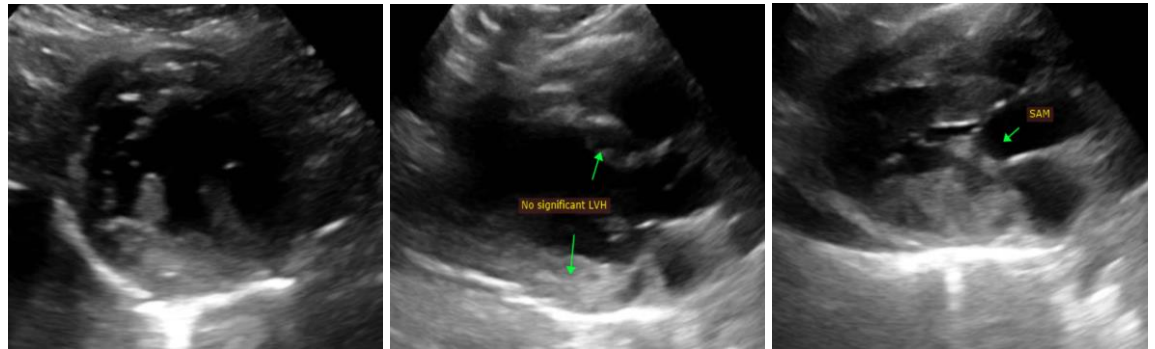
SEX

Male Neutered

IMAGES

AGE

1 year



WEIGHT

8.4lbs; 3.8kgs

The information and recommendations provided are based on the images presented by the referring veterinarian. No evaluation can be communicated regarding pathology that was not visible in the image/video clips provided.

INTERPRETED BY

Maggie Machen Lamy,
DVM, DACVIM
(Cardiology)

Thank you for this referral. This report was generated using transcription software, and minor dictation errors may be present. If the clinical or image interpretation does not parallel your findings or if I can be of any further assistance, please contact me.

IMAGING PERFORMED BY

Loetitia St-Jacques,
LVT/RVT

Maggie Machen Lamy, DVM
Diplomate of the American College of Veterinary Internal Medicine (Cardiology)
info@sonopath.com

HOSPITAL NAME

Sierra Animal
Wellness Center

REFERRING VET

Dr. Roberts

INVOICE

24039

DATE

5/4/22